

# Invasive *Streptococcus pneumoniae* Infection in an Afebrile Adolescent With HIV

---

## Authors:

**Sandra M. Camacho-Gomez, MD, and Yekaterina Sitnitskaya, MD**

*Department of Pediatrics, NYC Health + Hospitals/Lincoln, The Bronx, New York*

## Citation:

Camacho-Gomez SM, Sitnitskaya Y. Invasive *Streptococcus pneumoniae* infection in an afebrile adolescent with human immunodeficiency virus [published online November 14, 2017]. *Consultant360*.

## Introduction

The risk of invasive pneumococcal disease (IPD) is increased in immunocompromised persons, including HIV-infected persons, compared with immunocompetent persons.<sup>1-4</sup> Therefore, despite a significant reduction of IPD cases in the HIV-infected population in the highly active antiretroviral therapy (HAART) era<sup>5</sup> and in the post-pneumococcal-conjugate vaccine (PCV) era, the risk of IPD is generally still higher in immunocompromised patients.<sup>6</sup> However, the clinical presentation is the same in those with and without HIV infection.<sup>4</sup> *Streptococcus pneumoniae* is a major cause of bacteremia, which presents as fever with or without focus. We present a very unusual case of afebrile *S pneumoniae* lobar pneumonia and empyema in a fully vaccinated, infected adolescent.

## Case Presentation

An 18-year-old boy with perinatal HIV and hepatitis C coinfection, cirrhosis, coagulopathy, and chronic thrombocytopenia, presented with 4 days of cough and 2 days of right chest pain and

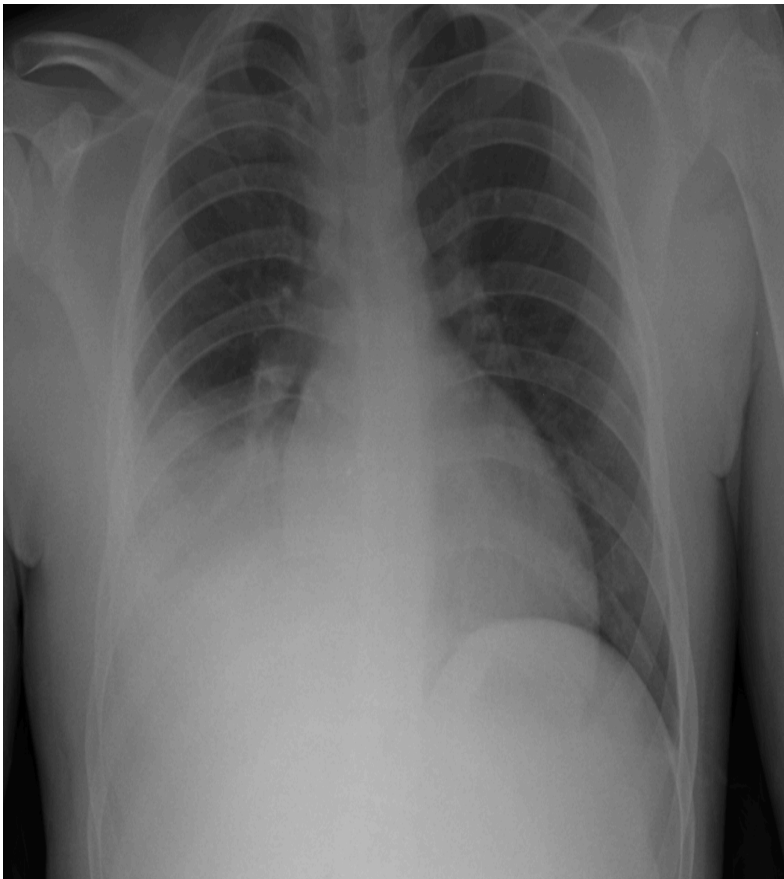
dyspnea, but no fever. The patient was not adherent to antiviral medications. His latest CD4 lymphocyte count was 11%, and his viral load was 28,300 copies/ml.

The patient had received 2 doses of PCV-13 and 3 doses of pneumococcal polysaccharide vaccine (PPV-23), most recently at age 16 years. He had no previous history of IPD.

The patient appeared ill but he was alert and oriented. His temperature was 37°C, respiratory rate was 24 breaths/min, heart rate was 99 beats/min, blood pressure was 115/48 mmHg, and oxygen saturation was 98% on room air.

The patient had subcostal, intercostal and suprasternal retractions, decreased breath sounds, and tracheal breathing in the right base. The spleen was palpable 2 cm below the costal margin. The rest of the physical examination findings were unremarkable.

The white blood cell (WBC) count was 7800/ $\mu$ L, the platelet count was  $38 \times 10^3/\mu$ L, blood urea nitrogen level was 36 mg/dL, and creatinine level was 3.05 mg/dL. A chest radiograph showed right lower-lobe consolidation and moderate effusion, findings that were confirmed with chest ultrasonography (**Figure**).



Initial treatment included ceftriaxone, azithromycin, and trimethoprim-sulfamethoxazole. A chest tube placed for 5 days yielded drainage of approximately 4000 mL of purulent material. The pleural examination showed gram-positive cocci in pairs and 4+ WBCs, but cultures had no bacterial growth. Blood cultures grew pan-sensitive *S pneumoniae*.

The patient was discharged after 10 days of treatment with oral amoxicillin. At follow-up 2 weeks later, he was asymptomatic and had normal findings on lungs auscultation. The patient had restarted HAART and reported full medication adherence.

## Discussion

Current guidelines recommend immunizing patients at risk for IPD with PCV-13 and PPV-23.<sup>7</sup> When it was introduced as PCV-7, the pneumococcal vaccine led to a more than 90% reduction in IPD,<sup>8</sup> and later PVC-13 further broadened protection.<sup>9,10</sup> In the past, among HIV-infected persons, bacterial pneumonia occurred with increased frequency with any CD4 lymphocyte count,<sup>2,3,11</sup> but it developed more frequently among those with CD4 lymphocyte count of less than 200/mm<sup>3</sup>.<sup>3</sup>

Although our patient had been appropriately vaccinated, he was not adherent to HAART and had a significant decline in the CD4 lymphocyte count during the preceding year; this probably contributed to the development of IPD. In addition to boosted pneumococcal vaccination, adherence to HAART must encouraged in HIV-infected youth, with emphasis on its role in prevention of severe illness requiring hospitalization and invasive procedures. The absolute leukocyte count is seldom over 15,000 cell/mL, and neutropenia may be more common in patients with HIV infection.<sup>2,11</sup> It is more helpful in an HIV-infected child with a fever to analyze the relative change in WBC from baseline as a predictor of bacteremia.<sup>4</sup>

Bacteremic pneumococcal pneumonia is a febrile illness.<sup>12,13</sup> There was a single case report of a pediatric patient with sickle cell disease who was afebrile despite *S pneumoniae* meningitis and bacteremia.<sup>14</sup> Here, we report a case of afebrile IPD in an immunocompromised patient with HIV infection.

## Conclusion

Although extremely rare, afebrile IPD is possible and should be considered, especially in an immunocompromised host.

## References

1. Centers for Disease Control and Prevention. Pneumococcal disease. <http://www.cdc.gov/pneumococcal/about/risk-transmission.html>. Updated September 6, 2017. Accessed November 6, 2017.
2. Gesner M, Desiderio D, Kim M, et al. *Streptococcus pneumoniae* in human immunodeficiency virus type 1-infected children. *Pediatr Infect Dis J*. 1994;13(8):697-703.
3. Hirschtick RE, Glassroth J, Jordan MC, et al; Pulmonary Complications of HIV Infection Study Group. Bacterial pneumonia in persons infected with the human immunodeficiency virus. *N Engl J Med*. 1995;333(13):845-851.
4. Janoff EN, Breiman RF, Daley CL, Hopewell PC. Pneumococcal disease during HIV infection: epidemiologic, clinical, and immunologic perspectives. *Ann Intern Med*. 1992;117(4):314-324.

5. Kapogiannis BG, Soe MM, Nesheim SR, et al. Trends in bacteremia in the pre- and post-highly active antiretroviral therapy era among HIV-infected children in the US Perinatal AIDS Collaborative Transmission Study (1986-2004). *Pediatrics*. 2008;121(5):e1229-e1339.
6. Rose MA, Christopoulou D, Myint TTH, de Schutter I. The burden of invasive pneumococcal disease in children with underlying risk factors in North America and Europe. *Int J Clin Pract*. 2014;68(1):8-19.
7. Pneumococcal infections. In: Kimberlin DW, Brady MT, Jackson A, et al, eds. *Red Book: 2015 Report of the Committee on Infectious Diseases*. Elk Grove Village, IL: American Academy of Pediatrics; 2015:626-638.
8. Maraqa NF. Pneumococcal infections. *Pediatr Rev*. 2014;35(7):299-310.
9. Moore MR, Link-Gelles R, Schaffner W, et al. Effectiveness of 13 valent pneumococcal conjugate vaccine for prevention of invasive pneumococcal disease in children in the USA: a matched case-control study. *Lancet Respir Med*. 2016; 4(5):399-406.
10. Tan TQ. Pediatric invasive pneumococcal disease in the United States in the era of pneumococcal conjugate vaccines. *Clin Microbiol Rev*. 2012;25(3):409-419.
11. Dayan PS, Chamberlain JM, Arpadi SM, Farley JJ, Stavola JJ, Rakusan TA. *Streptococcus pneumoniae* bacteremia in children infected with HIV: presentation, course, and outcome. *Pediatr Emerg Care*. 1998;14(3):194-197.
12. Toikka P, Virkki R, Mertsola J, Ashron P, Eskola J, Ruuskanen O. Bacteremic pneumococcal pneumonia in children. *Clin Infect Dis*. 1999;29(3):568-572.
13. Peters TR, Abramson JS. *Streptococcus pneumoniae* (pneumococcus). In: Kliegman RM, Stanton BF, St. Geme JW III, Schor NF, Behrman RE, eds. *Nelson Textbook of Pediatrics*. 19th ed. Philadelphia, PA: Elsevier Saunders; 2011:910-914.
14. Santoro JD, Case AE, El-Dahr J, Kanter J. A case of invasive *Streptococcus pneumoniae* in an afebrile adolescent with sickle cell disease. *Clin Pediatr (Phila)*. 2013;52(12):1173-1175.